

# Analysis of Breast Diseases Examination with Thermal Texture Mapping, Mammography and Ultrasound

Yune Yuan , Qing Wang, Yan Tan , Li Rong, Song San Tai, Li Ji Ye, <sup>1</sup> Zhongqi Liu <sup>2</sup>

<sup>1</sup> Institute of Basic Medical Science, China Army General Hospital, Beijing, China

<sup>2</sup> China People Health Association, Beijing, China.

**Abstract:** This paper will compare diagnostic values of Thermal Texture Mapping (TTM), mammography and ultrasound in relating breast disease. Using pathological finding as gold standard, the results were compared with that of TTM , mammography and ultrasound. There being 25 cases of malignant and 13 cases of benign, the correlation rate of TTM with pathological finding (100%,96%)respectively, were superior to the correlation rate of mammography , ultrasound with pathological finding (88.9%,63.6%,90.5%,63.6%). TTM, on the differential diagnosis of breast disease, were superior to mammography and ultrasound .

**Keywords:** Thermal Texture Mapping (TTM), Mammography (MMT) , Ultrasound, Breast disease, Thermography, Infrared Imaging.

## I. INTRODUCTION

In recent years, the occurrence of breast cancer is dramatically increasing. Doctors around the world are likely searching for a new kind of technique, that can be used for screening breast cancer more simply and more specifically. Thermal texture mapping system ( TTM), as one of the functional diagnostic procedures, may detect the abnormal metabolism of body tissues at an early stage. A group of 38 females with breast abnormalities, who were prepared for surgery, underwent **double-blind study** on TTM, ultrasound and mammography with molybdenum target tube (MMT) simultaneously and compared with the pathological results after surgery. TTM was used to explore the position in differentiation between the benign and malignant breast abnormalities.

## II. MATERIAL AND METHODS

Thirty eight females age from 20 to 78 were hospitalized in the surgery sections of 301 and 307 hospitals between Dec.20.2003 – Mar.20,2004. The main symptoms were palpable masses in their breasts. After receiving TTM,

ultrasonography and MMT, all patients underwent surgery. Histology of the tumor sample demonstrated malignant in 25 and benign in the others.

The apparatus used for the study is a TSI-21 TTM system manufactured by Bioyear groups company. Its main parameters include: a resolving power of 0.1C, and scanning period of 5 seconds or less, and the assaying precision of 0.1°C. Computer processing and printing start while the scanning distance reaches 1 to 3 meters.

The room temperature was controlled between 20 to 24C, and the patients were asked to remove their clothes or just cover the lower part of the body after having 10 minutes rest. Respect for privacy and patient comfort were kept in mind. Their hands should not touch the body. After focusing, the images of head, breast and abdomen were taken anteroposteriorly, adding breast oblique pictures from both sides and were stored. The abnormal thermo-sources in the images were digitized from tomography and the temperatures was measured for evaluation.

The evaluation items of TTM for breast masses included: endocrino-logical triple images (pituitary, thyroid and pancreas ), abnormal axillary thermo-source, abnormal breast thermo-source, abnormal vascular thermo-source, abnormal nipple thermo-source, abnormal areola of nipple thermo-source. The thermo-sources were analyzed according to their morphology, structure, depth and temperatures measured. The diagnostic standards for malignant breast tumor included dyssymmetry thermo-point, abnormal symmetry angiography, temperature deviation in the thermography, the positive thermography in the thermo-tomography and thermo-point in the attenuation images[1][2][3].

## III. RESULTS

The correlation rates between TTM, MMT, ultrasonography and pathological results in the 38 cases is shown in table 1.

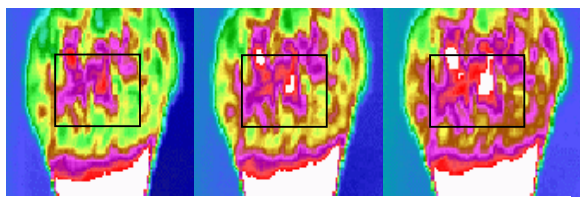
**TABLE I**  
THE CORRELATION RATE BETWEEN TTM, MMT, ULTRASOUND AND PATHOLOGICAL RESULTS

RESULT	PATHOLOGY	TTM		MMT		ULTRASOUND	
		+ (%)	- (%)	+ (%)	- (%)	+ (%)	- (%)
Malignant	25	24 (96%)	1 (4%)	16 (88.9%)	2(11.1%)	19(90.5%)	2(9.5%)
Benign	13	0	13(100%)	4(36.4%)	7(63.6%)	4(36.4%)	7(63.6%)
Total	38	38		29		32	

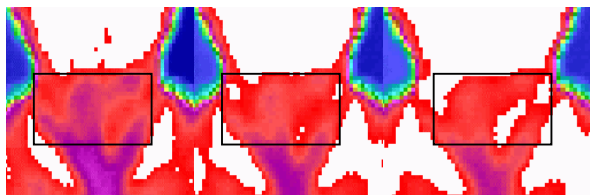
There were 25 cases of malignant and 13 cases of benign, the correlation rate of Thermal Texture Mapping with pathological finding (100%,96%) respectively, were superior to the correlation rate of mammography , ultrasound with pathological finding (88.88% , 63.63%, 90.47%, 63.63%).

The correlation rate between TTM and pathology for the diagnosis of benign breast disease and breast cancer were 100% and 96%, respectively, which were superior to **the correlation rate between MMT, ultrasound and pathology.**

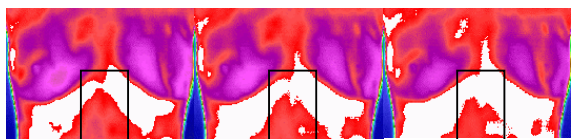
The positive rate of endocrino-logical triple images of breast diseases was higher in malignant than in benign.



(a) Endocrine logical triple signature 1




(b) Endocrine logical triple signature 2



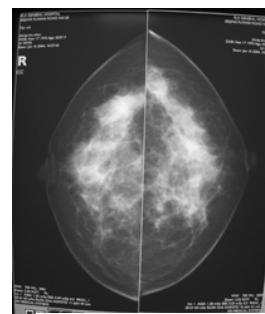
(c) Endocrine logical triple signature 3

Figure 1 Endocrine logical triple images of breast

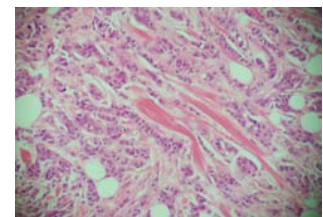
Case 1 of benign bumps with abnormal breast thermo-source that was regular morphology and less vascular, nipple, areola of nipple thermo-source, is shown figure 2.



(a) TTM image of left breast benign bumps



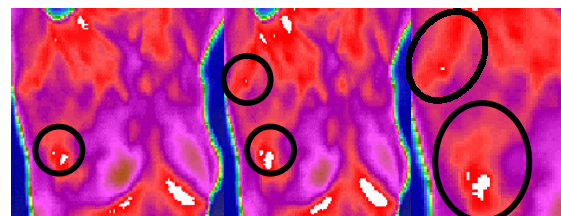
(b) MMT image of left breast



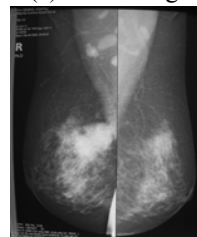
(c) Pathology image of left breast fatty tumor

Figure 2 Benign bumps compared between TTM and MMT Band confirmed by pathology. (a)TTM image of January 16,2004 indicates the slices of abnormal thermo-source in the out-upper quadrant on left breast. These slices of thermo-source show the regular morphology and lesser vascular. (b) MMT image of January 16,2004 shows a 0.6x0.5cm, clear edged lumps in the outboard on the left breast. (c) Pathology diagnosis is fatty tumor

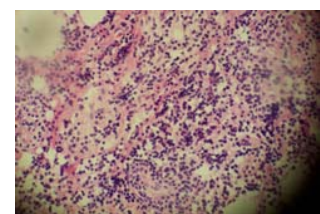
Case2 of malignant bumps with abnormal breast thermo-source that was irregular morphology and more vascular , **accompanied with swollen axillary lymph node** , was shown figure 3;



(a) TTM image of right breast malignant bumps



(b) MMT image of right breast



(c) Pathology image of right breast carcinoma

Figure 3 Malignant bumps compared between TTM and MMT and confirmed by pathology .(a)TTM image of February 4, 2004 indicates the slices of abnormal breast thermo-source that were of irregular morphology, more vascular and higher heat values accompanied with swollen axillary lymph node. (b) MMT image taken of February 4, 2004 shows a burred boundary mass with sand-grained calcification in the outboard on the right breast. (c)Pathology is infiltrated duct carcinoma.

Furthermore, endocrine-logical triple images are the most important in differential diagnosis of malignance and benign breast disease.

TTM evaluation results for the benign and malignant breast diseases are shown in table 2.

**TABLE II**  
TTM EVALUATION RESULTS FOR THE BENIGN AND MALIGNANT BREAST DISEASES

TTM Elevation Standard	Result	Malignant Patient / ( % )	Benign Patient / ( % )
Endocrinological Triple graphs	Positive	24/(96)	5/(38)
	Negative	1/ ( 4 )	8/(62)
Abnormal Breast Heat Source	Positive	25/(100)	12/(92.4)
	Negative	0	1/(7.6)
Abnormal Axillaries Heat Source	Positive	15/(60)	8/(61.5)
	Negative	10/(40)	5/(38.5)
Abnormal Vascular Heat Source	Positive	23/(92)	4/(30.7)
	Negative	2/ ( 8 )	9/(69.3)
Abnormal Nipple Heat Source	Positive	20/(80)	2/(18.4)
	Negative	5/ ( 20 )	11/(84.6)
Abnormal Areola Heat Source	Positive	12/(48)	3/(23.1)
	Negative	13/(52)	10/(76.9)

#### IV. DISCUSSION

Mammographic imaging using x-ray tubes with molybdenum, known for its low radiation, clear film and diagnostic accuracy, has been widely accepted by the doctors in the clinic. Unfortunately, it is rather difficult to obtain clear pictures with MMT detecting abnormalities of the densely breasts in adolescent females due to its weak penetration. It is not easy to obtain correct diagnosis of breast cancer in its early stages. There is speculation limit in the special areas such as laterosuperior quadrant of the breasts and axilla. There are also other disadvantages such as high cost and radiation damage , which result in limited usage. Ultrasonography is useful for tumor localization and identification of cystic tumors, but not good at differentiation of malignance from the benign abnormalities.

Traditional infrared scanners are simple, harmless, and sensitive at the early stages of the tumor; however the poor penetration and localization, and temperatures

assessment being limited on the body's surfaces result in a higher false-positive rate. Compared with the traditional infrared scanner, besides of its advantages, TTM is not only capable of measuring depths and values of thermo-source which raise the specificity of assaying, but also capable of evaluating the patients' general conditions including detecting metastasis of the lymph node in the axillary and superclavicular areas and other organs.

##### A. The mechanism of TTM diagnostic functions

Thermo-radiation that transferred heat energy from the inside to the surface of the body, reflects the subtle metabolism changes of living cells in the body. Using infrared scanners to receive signals from the heat radiation, TTM reconstructs a cell's of metabolic extent map, which reflects the target organs or tissues by computerized processing of the data with specific regulations and measurements, and which measure the depths and values of the thermo-source to diagnose according to the thermo-deviations between normal and abnormal tissues, and provide the quantity evidence for diagnosis[2].

Normal breasts are symmetrical, in which blood vessels are evenly distributed and metabolism of the acinic tissues is accordant with the adjacent structures. When cell differentiation is nearly mature, benign growth in the breasts develops rather slowly, so there is a little or no temperatures difference between them. The metabolism of cancer cells is very active, therefor its blood circulation is very rich. The cancer cells may develop several vasoactive agents such as bradykinin. The thermo energy transferred from the source of the dermis results in a high temperature area, in the other hand, the thermo energy carried by blood stream is transferred to the venous vessels in the superficial area and forms abnormal angi-images on the thermogram. There is no fat in the areola of nipple for heat isolation and the venous vessel plexus in the superficial area communicates with the ones in the deep area of the Haller's circle just behind the areola of nipple, so high temperature in the area shows the significant in diagnosis of breast cancer.

##### B. The value of TTM for breast diseases differentiation

Jones reported that among more than 20,000 cases from 1967 to 1972, the positive rates were 70% and nearly 90% in breast cancers in the I ,II stages and III,IV stages, respectively.[4] The positive rate was 23% in 4,393 cases without symptoms with infrared scanner. Of the 1,028 positive cases there were 2.4% cancer patients found using x-ray mammography, which was higher than the rate (0.7%) for the same test in the general survey of breast cancer[5]. At the same time at the Seventh International Cancer Conference held by the American Cancer Association and the National Cancer Institute of U.S. Gerald D .Dodd reported that in a general survey of breast cancer for the females aged 40 years or more, 5%

of those who were found have abnormal infrared results accounted for 15% to 20 % of the total numbers, and were suggested to undergo biopsy[6]. The study in this paper shows that TTM was found to be superior to MMT and ultrasonography for detection of malignant among the benign diseases of breast.

Comparing TTM with other modern diagnostic techniques, TTM focuses on cell metabolism and provides both morphological evidence in anatomy and functional evidence in physiology, and reached concordance between the systematical examination and dynamic real time examination. TTM was able to find more than 80% of micro-pathological changes in the tissues at its early stage[7][8]. Feig et al reported that infrared images are 4 folds more sensitive than physical examination among 16,000 females who underwent general survey of breasts[9]. Wallace found that the detection rates were 0.27% and 1.9% in the x-ray mammography and infrared pictures, respectively[10]. In 1980 Gautherie and Gros demonstrated that 1,245 females with all normal results including physical examination, mammogram, ultrasonography and biopsy, but infrared confirmed more than one third of them as having breast cancer during the 5-years follow-up. It is concluded that breast thermography is not only an indicator of breast cancer, but also may detect breast abnormalities that develop quickly[11]. In 1983 Isard HJ concluded that a combination of breast thermography and mammography raised the accuracy of diagnosis and reduce the amount of unnecessary surgery after exploring the characteristics of breast thermography and ultrasound[12]. As one of the functional diagnostic techniques, TTM is not only able to detect abnormal metabolism of the cells in the early stage with noninvasive techniques, but also evaluate and analyze the depth, morphology and the thermo-values real-time. All 38 cases but one coincided with the pathological results, and the diagnostic accuracy was 97.35%. It is concluded that TTM can be used to evaluate the sub-healthy conditions in humans as well as locate tumors at very early stages for the majority of diseases; especially those that develop very slowly, and is harmless to the human body and uses no environment pollutants.

#### ACKNOWLEDGMENT

The authors are grateful to colleagues for the very instructive suggestions and support of clinic study which led to the much improved quality of the paper: Dr. Wentong Xiu, Dr. Yanjun Zhang from Department of Genial Surgical; Dr. Mei Liu from Department of Pathology, Army General Hospital, Beijing, China, Prof. Wanchang Qin from 304 Hospital, Beijing, China, Dr. Xianwu Tang from Tsing Hua University, Dr. Jingbing Liu Department of Genial Surgical, Beijing

Long Fu Hospital, Dr. James Wu from TTM International Inc. USA.

#### REFERENCES

- [1] Z.Q.Liu and CHEN WANG: Method and Apparatus for Thermal Radiation Imaging, United States Patent No.6,023,637,8 FEB 2000
- [2] Hairong Qi, Phani Teja Kuruganti, Zhong Qi Liu : Thermal Texture Maps System on the Early Diagnosis of Breast Cancer. The 207th Xiangshan Science Conference P8-11, Sep.3-5,2003.
- [3] Yasuhiko Ohashi and Isao Uchida: Application of Dynamic Thermography on Breast Cancer diagnosis. *IEEE ENGINEERING IN MEDICINE AND BIOLOGY* July/August 34-42,1998
- [4] Jone CH: Thermography of female breast. In; Parsons CA: Diagnosis of breast disease. *Baltimore: University Park Press*, pp214-234,1983
- [5] Isard HJ, Becker W, Shilo R, et al: Breast thermography after four years 100 studies. *Am J Roentgenol* 115:811-821,1972
- [6] Dodd GD: Thermography in breast cancer diagnosis. In: *Abstracts for the Seventh National cancer Conf Proc*. Losgeles, CA, Sept, 27-29,1972
- [7] Jonathan F Head, Fen Wang, Charles A, Lipari, Robert, Elliott; The Important Role of Infrared Imaging in Breast Cancer. *IEEE ENGINEERING IN MEDICINE AND BIOLOGY* May/June 52-57,2000
- [8] Iwao Fujimasa: Pathophysiological Expression and Analysis of Far Infrared Thermal Images. *IEEE ENGINEERING IN MEDICINE AND BIOLOGY* July/August 34-42,1998
- [9] Feig SA, Shaber GS, Schwartz GF et al.: Thermography, mammography, and clinical examination in breast cancer screening. *Radiology* 122:123-127,1977
- [10] Wallace JD: Thermography examination of the breast: In: Gallagher HS(Ed): *Early Breast Cancer: Detection and Treatment*. New York: Wiley, 13-19,1975
- [11] Gautherie M and Gros: Breast thermography and cancer risk prediction. *Cancer* 45:51-56,1980
- [12] Isard HJ: Other imaging techniques. *Cancer* 53:658-664,1984